

Thumb Trapeziometacarpal Arthritis: Treatment with Ligament Reconstruction Tendon Interposition Arthroplasty

Ashkan Ghavami, M.D.

Scott N. Oishi, M.D.

Dallas, Texas

Learning Objectives: After studying this article, the participant should be able to: 1. Understand the pathomechanical and biochemical basis for thumb trapeziometacarpal joint degeneration. 2. Diagnose and grade trapeziometacarpal joint disease based on presentation, physical examination (including provocative testing), and radiographic evidence. 3. Understand the principles of ligament reconstruction and tendon arthroplasty procedures. 4. Describe the surgical technique for ligament reconstruction tendon interposition arthroplasty and its variants.

Background: Osteoarthritis of the trapeziometacarpal joint is the second most common site of degenerative joint disease in the hand, and mostly affects postmenopausal women. Degenerative arthritis of the thumb trapeziometacarpal joint is associated with a lack of bony constraints and laxity of the supporting ligaments, particularly the anterior oblique (“beak”) ligament, which is consistently implicated in disease progression. Resultant increases in joint stress loads leads eventually to metacarpal and trapezium articular destruction, thumb instability, and pain.

Methods: In this article, the authors review the diagnosis and treatment modalities available to the surgeon in the treatment of patients with trapeziometacarpal osteoarthritis. The technique of ligament reconstruction tendon interposition arthroplasty is discussed in detail.

Results: Ligament reconstruction tendon interposition arthroplasty procedures center on three common principles: (1) excision of the diseased trapezium; (2) reconstruction of the beak ligament; and (3) interposition of a tissue substance to maintain metacarpal position.

Conclusions: Both conservative and surgical management can be effective in the treatment of trapeziometacarpal arthritis, when properly selected. The success of ligament reconstruction tendon interposition arthroplasty in treating trapeziometacarpal arthritis has withstood the test of time. (*Plast. Reconstr. Surg.* 117: 116e, 2006.)

Trapeziometacarpal arthritis is the second most common degenerative joint disease in the hand, commonly affecting women in their fifth to sixth decades of life.¹⁻⁴ A study by Kelsey et al. estimated that one in six women had radiographic evidence of basal joint arthritis, compared with only 5 percent of men.⁵ Others report a prevalence of 33 percent in postmenopausal women (with one-third being symptom-

atic) versus an 11 percent rate in men older than 55 years.^{6,7} Female predisposition may be attributable to hormonal factors; increased ligament laxity; and presence of a smaller, less congruous trapeziometacarpal joint, all resulting in greater joint contact pressure.^{8,9}

The trapeziometacarpal joint is unique in that it is a biconcave-convex “saddle” joint. In addition, a lack of bony constraints places a greater reliance on the supporting ligamentous structures for stability. Before more contemporary studies,^{10,11} Eaton and Littler^{4,12} had already identified the anterior oblique beak ligament (or deep anterior oblique ligament^{13,14}) as the primary trapeziometacarpal joint stabilizer, supporting the need for its reconstruction. Laxity of

From the Department of Plastic and Reconstructive Surgery, The University of Texas Southwestern Medical Center.

Received for publication June 29, 2005; revised August 23, 2005.

Copyright ©2006 by the American Society of Plastic Surgeons

DOI: 10.1097/01.prs.0000214652.31293.23

the beak ligament, along with attenuation of other ligaments (discussed below), allows for greater stress loads on the trapeziometacarpal joint, particularly during pinch. Even under normal circumstances, a pinch force of 1 kg at the thumb tip can translate to a 13.42-kg force at the trapeziometacarpal joint.⁸

The goals of treatment are to alleviate pain and restore joint stability. Fortunately, roles for both conservative and surgical options currently exist to successfully treat trapeziometacarpal joint pain and restore joint stability. Surgery is commonly offered to the symptomatic patient when conservative measures have failed or when there is advanced disease. Ligament reconstruction tendon interposition or other surgical techniques are often required in Eaton stage II through IV disease. Numerous technical variations of ligament reconstruction and tendon interposition arthroplasty popularized by Burton and Pelligrini¹⁵ have been described in the literature^{16–20} and all share three common treatment principles: (1) removal of the abnormal bony surface (trapezium excision), (2) reconstitution of ligamentous (anterior oblique ligament) support, and (3) interposition of a substance (usually tendon) to help maintain the metacarpal suspension.

Trapezium excision alone was first advocated by Gervis in 1949,²¹ and although popularity had declined because of concerns for the long-term pain relief and stability,²² some surgeons have stimulated renewed interest in the procedure.^{23–25} Recently, studies comparing trapeziectomy alone, trapeziectomy with tendon interposition, and ligament reconstruction techniques have reported no difference in pain relief, hand function, and thumb strength.^{26,27} Follow-up periods for these studies have been short. However, ligament reconstruction techniques that include an interposition component are still more popular today. The thought is that they more closely address the anatomical problems inherent to trapeziometacarpal joint arthrosis and produce long-lasting results.^{10,17,19,20,22,28} A study by Tomaino et al.¹⁷ demonstrated joint stability, excellent pain relief, and a significant increase in strength for as long as 11 years postoperatively.

Appropriate treatment of trapeziometacarpal joint arthritis can produce predictable long-term patient satisfaction, making it an important procedure to be understood and applied by hand surgeons with an interest in treating trapeziometacarpal joint arthritis. This report discusses the anatomy, pathophysiology, diagnosis, and current surgical treatment of trapeziometacarpal

joint arthritis, particularly the ligament reconstruction tendon interposition–type arthroplasties.

ANATOMY AND BIOMECHANICS

Comprehensive knowledge of the ligamentous anatomy of the trapeziometacarpal joint is required to understand the rationale for performing the various trapeziometacarpal joint reconstructions. Unlike the hinge-type joints that dominate the hand, the trapeziometacarpal or basal joint of the thumb is a uniquely structured biconcave-convex saddle joint. The paucity of bony constraints forces the trapeziometacarpal joint to rely on the surrounding ligaments for support, which subjects the joint to abnormal pressure loads.^{13,14,17}

The trapezium endures both axial and cantilever stress loads, particularly during lateral pinch and grasp maneuvers.^{11,13,29} Postmortem histologic and biochemical studies have demonstrated a predominant palmar pattern of articular surface destruction to be associated with beak ligament attrition and gross ligament detachment from the native position.^{3,30–32} In addition, lateral pinch cadaver models demonstrate mostly palmar-located eburnation patterns of the articular surfaces.^{32–34}

The ligamentous anatomy is complex and has been studied by numerous authors.^{11,13,14,17,19,35} Figure 1 illustrates how ligamentous laxity can contribute to radial deviation and extension from cantilever bending forces to produce the zigzag collapse deformity.¹³ Using arthroscopic assistance, Bettinger et al.¹³ described 16 ligaments that stabilize the trapeziometacarpal joint; however, a detailed discussion of all of them are beyond the scope of this article. Seven of these ligaments are thought to be directly responsible for trapeziometacarpal joint stability (Table 1).^{13,14} These are the deep anterior oblique or beak ligament, the superficial anterior oblique ligament, the dorsoradial ligament, the ulnar collateral ligament, the posterior oblique ligament, the intermetacarpal ligament, and the dorsal intermetacarpal ligament (Fig. 2). The beak ligament has long been regarded as the most significant supporting structure of the trapeziometacarpal joint. Current research, based on biochemical and histologic analysis, continues to describe the deep anterior oblique ligament as being the primary stabilizer of the trapeziometacarpal joint.^{3,30,36}

Joint surface beak ligament attrition plays a fundamental role in the pathophysiology of trapeziometacarpal joint arthritis, which has led to the popularity of ligament reconstruction.^{33,34} The beak ligament is so named because its obliquely

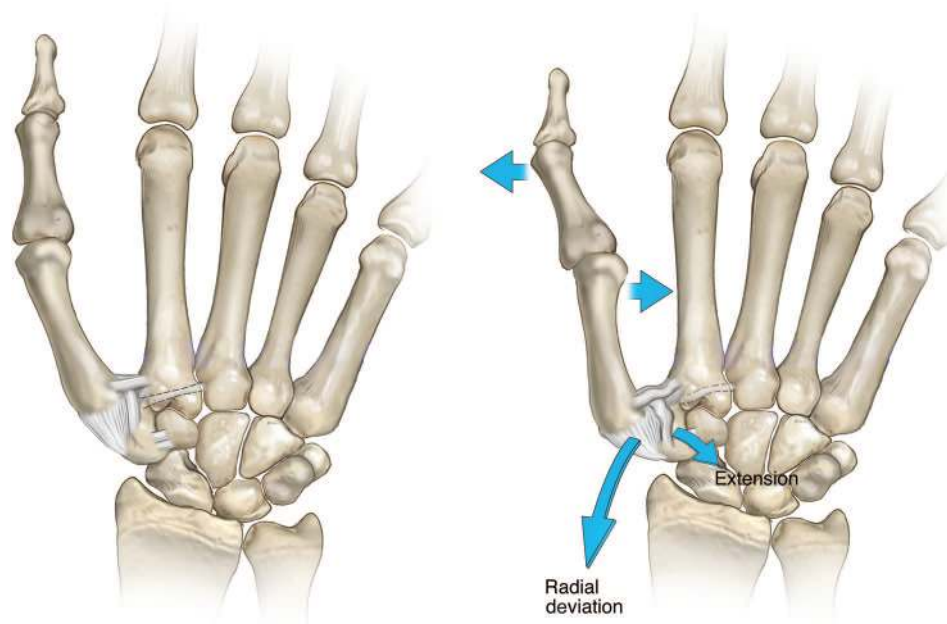


Fig. 1. Presumed ligament laxity results in trapeziometacarpal joint instability. Trapezial cantilever forces cause radial deviation and extension of the thumb ray to produce a zigzag deformity.

oriented fibers originate just ulnar to the volar styloid process of the first metacarpal base (beak) and insert onto the volar central apex of the trapezium. The deep anterior oblique ligament serves as a pivot point, particularly during thumb pronation (rotation), and becomes taut in abduction or extension to prevent ulnar subluxation of the thumb metacarpal.^{13,14,34}

Biochemical analysis of the arthritic trapeziometacarpal joint hyaline cartilage reveals a loss of glycosaminoglycan from the extracellular matrix and sparing of the collagenous network in the palmar region, where osteoarthritic disease first originates.³ This selective biochemical process seems to be responsible for the progression of trapeziometacarpal joint disease. Histologic studies reveal that the attritional degeneration of the deep anterior oblique ligament at its attachment to the palmar lip of the metacarpal occurs before the cartilaginous destruction.³⁰ Detachment of the deep anterior oblique ligament results in dorsal

translation of the metacarpal, which supports beak ligament reconstruction in early and late disease.^{4,10,12}

Six other ligaments play contributing roles in trapeziometacarpal joint stability. The superficial anterior oblique ligament is longer than the deep anterior oblique ligament and provides the laxity necessary for pronation.^{14,33} The dorsoradial ligament is the shortest and thickest ligament of the trapeziometacarpal joint and may be the first to become taut during dorsal and dorsoradial subluxation^{13,14}; however, its significance in providing trapeziometacarpal stability has been debated (P. Bettinger et al., unpublished data).^{14,33,37} The intermetacarpal ligament assists the dorsoradial ligament in constraining radial translation and subluxation of the first metacarpal base.^{13,14} The dorsal intermetacarpal ligament (along with the intermetacarpal ligament) may also help restrain the first metacarpal from collapsing proximally after trapezial excision.¹⁴

Table 1. Major Ligaments of the Trapeziometacarpal Joint

Ligament	Description
Deep anterior oblique	Beak ligament, primary trapeziometacarpal joint stabilizer, pivot point, limits dorsal translation
Superficial oblique	Helps stabilize volar metacarpal subluxation
Dorsoradial	Shortest and thickest ligament in the trapeziometacarpal joint
Ulnar collateral	Helps limit volar subluxation
Intermetacarpal	Stabilizes metacarpal during radiovolar translation
Dorsal intermetacarpal	May help restrain metacarpal from collapse after trapezial excision

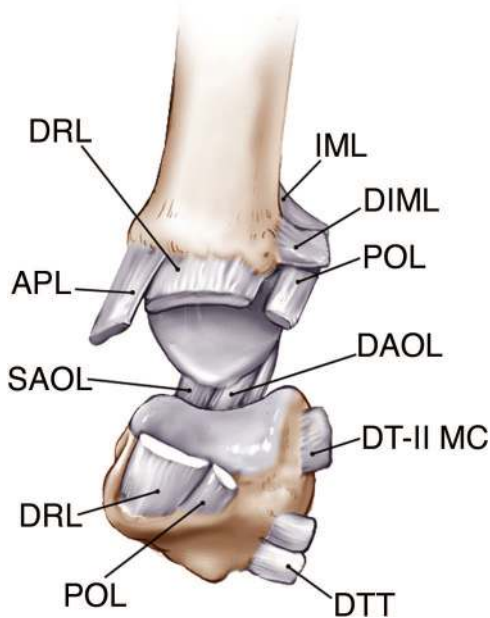


Fig. 2. The trapeziometacarpal joint is hinged open from the dorsum to reveal the ligaments. The deep anterior oblique (beak) ligament (*DAOL*) is consistently implicated in trapeziometacarpal joint disease progression. Other ligaments include the superficial anterior oblique ligament (*SAOL*), the posterior oblique ligament (*POL*), the dorsoradial ligament (*DRL*), the dorsal intermetacarpal ligament (*DIML*), the intermetacarpal ligament (*IML*), the dorsal trapeziotrapezoid ligament (*DTT*), and the dorsal trapezio-second metacarpal ligament (*DT-II MC*). *APL*, abductor pollicis longus tendon.

PREOPERATIVE EVALUATION

Stages

Historically, several staging systems have been created to correlate radiographic evidence of trapeziometacarpal joint arthritis with clinical symptomatology.^{38–40} However, pain and other symptoms do not seem to correlate well with radiographic findings.^{40,41} A patient can have severe pain with a low radiographic stage or have no pain with pantrapezial involvement. Littler and Eaton⁴⁰ described a purely radiograph-based staging system that is the most common staging system used today (Fig. 3). The characteristic findings in each stage are listed in Table 2. Eaton stage I demonstrates a normal articular surface, and joint space widening caused by effusions and/or ligament laxity can also be present. Stage II displays mild joint narrowing, mild sclerosis, more than one-third subluxation, a normal scaphotrapezial joint, and osteophytes or debris that are smaller than 2 mm. Stage III involves significant joint narrowing, subchondral sclerosis, and osteophytes larger than 2 mm

in diameter. Stage IV now includes the scaphotrapezial joint in addition to trapeziometacarpal joint disease. A stage V has recently been suggested to account for pantrapezial arthritis.³⁶

Clinical Examination

Along with radiographic evaluation and staging, a thorough history and physical examination will help guide the treatment plan. Typically, patients will present with complaints of pain at the base of the thumb, often radiating to the thenar eminence or metacarpophalangeal joint. Pain is exacerbated by forceful pinching and grasping motions. Examples are turning keys and door-knobs, holding large containers, and unscrewing jar tops.⁴² With early disease, stiffness is usually not prevalent. Osteophytes may, however, lead to limited motion, eventually resulting in a dorsally fixed and subluxed joint that is adducted, with limited palmar abduction.^{12,42} The consequence of prolonged stiffness may be compensatory metacarpophalangeal joint hyperextension. Hyperextension greater than 30 degrees warrants arthrodesis or capsulodesis, along with surgical reconstruction of the trapeziometacarpal joint.¹⁶

Patients will commonly have tenderness to palpation at the radiovolar aspect of the joint regardless of the disease stage. If the scaphotrapezial joint (approximately 1 cm proximal to the trapeziometacarpal joint) is also tender, this may indicate stage IV disease. Earlier disease stages correlate with greater joint laxity, whereas stiffness is often present in late disease. Crepitus resulting from friction between eburnated joint surfaces is usually present with stage III or IV disease.

Provocative tests that illicit pain in the trapeziometacarpal joint have been described, and include the axial compression adduction test, axial compression rotation test (grind test), and the distraction test. The axial compression adduction test involves placing axial compression on the thumb as the subluxation is reduced. The grind test is performed by rotating the thumb metacarpal base while applying axial compression on the trapeziometacarpal joint. The distraction test also includes thumb rotation, but axial traction is also applied to stretch the inflamed ligaments in milder disease stage.

Imaging

Plain radiographs are all that are required in evaluation and staging of thumb trapeziometacarpal joint disease. Radiographs should include posteroanterior, lateral, and oblique views. Other

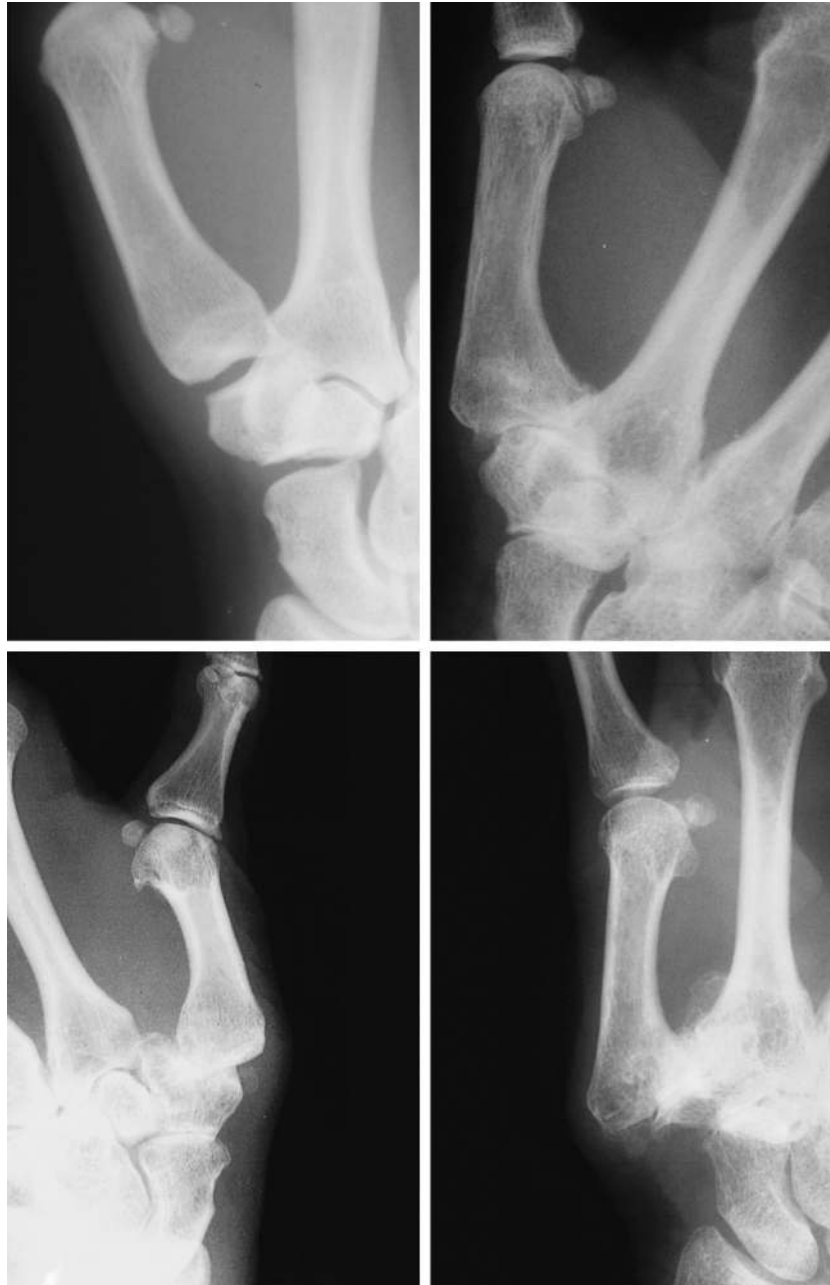


Fig. 3. Radiographs demonstrating Eaton stages I (above, left), II (above, right), III (below, left), and IV (below, right).

Table 2. Radiographic Staging*

Stage	Description
I	Normal joint, possible joint widening
II	Joint narrowing, debris, and osteophytes <2 mm
III	Joint space narrowing, osteophytes >2 mm
IV	Scaphotrapezoidal joint involved
V*	Pantrapezoidal arthritis (new stage)*

*Data derived from Tomaino, M. M. Thumb basal joint arthritis. In D. P. Green et al. (Eds.), *Green's Operative Hand Surgery*. 5th Ed. New York: Churchill Livingstone, 2005. Pp. 461–485.

views include the stress view, as described by Eaton and Littler,⁴ and the Roberts view. The stress view involves a posteroanterior view of both thumb trapeziometacarpal joints taken together as the patient pushes the radial aspect of one thumb with the other, causing metacarpal base lateral subluxation. The Roberts view is taken as an anteroposterior view of a hyperpronated hand and gives a clear image of all four trapezial articulations.

Differential Diagnosis

Thumb trapeziometacarpal arthritis can be confused with several disease entities that can have a similar presentation of pain in the base of the thumb (Table 3). However, careful clinical evaluation should confirm the diagnosis. Patients with de Quervain's disease will have tenderness at the tip of the radial styloid and along the first extensor compartment, rather than at the radiovolar trapeziometacarpal joint region. Flexor carpi radialis tenosynovitis can also confuse the diagnosis, but pain will be in a more ulnar location and be exacerbated with wrist flexion. Trigger thumb or subsesamoid arthritis can accompany trapeziometacarpal joint arthritis and should be ruled out.

Scaphoid fractures, particularly at the distal pole, can illicit pain and tenderness in the trapeziometacarpal joint region. However, a careful history will often reveal the original traumatic event. Male patients with trapeziometacarpal arthritis are probably more likely to have an associated traumatic cause, even a benign sprain.⁴³ Greater than one-third of patients may have concomitant carpal tunnel syndrome, warranting carpal tunnel release at the time of trapeziometacarpal arthritis surgery.⁴⁴

NONSURGICAL TREATMENT

Current nonsurgical treatment options for trapeziometacarpal arthritis include trials of nonsteroidal antiinflammatory drugs, thumb spica splinting, and intraarticular steroid injections.⁴⁵⁻⁴⁷ Swigart et al.⁴⁸ conducted a retrospective analysis of 130 thumbs treated with 3 to 4 weeks of splinting and found 76 percent of patients with Eaton stage I or II disease and 54 percent of patients with stage III and IV disease to have symptomatic improvement at 6-month follow-up. Day et al.⁴⁵ performed a prospective analysis of a single intraarticular steroid injection followed by 3 weeks of splinting in 30 thumbs. DASH (disabilities of the arm, shoulder, and hand) outcome-based analysis demonstrated 40 percent substantial relief regardless of radiographic stage. Eighty percent of Eaton stage I patients experienced pain relief at 18

months; only 25 percent of stage IV patients and approximately 35 percent of stages II and III patients had sustained relief.⁴⁵ These findings suggest that patients with Eaton stage I disease can be successfully treated with a steroid/splinting regimen, but as osteophytes develop and joint narrowing progresses (stages I and III), results become less predictable.

Some authors have recommended a trial of nonsteroidal antiinflammatory drugs and splinting with intrinsic and extrinsic muscle strengthening before steroid injections.⁴² Repeated steroid injections should be avoided, as they can further weaken the joint capsule.¹⁵

SURGICAL TREATMENT

Surgical reconstruction of the degenerative basal joint is indicated when conservative measures have failed to relieve pain and improve thumb function. Elderly patients with more advanced disease may have significant deformity but have less pain and may not need to undergo operative intervention. Eaton staging⁴⁰ can help guide the selection of specific procedures. Glickel⁴² and Tomaino et al.³⁶ discuss the algorithm for operation based on symptoms and Eaton staging. Stage I, with characteristic joint widening and ligament laxity, may be treated with Littler and Eaton^{4,12} anterior oblique ligament reconstruction using a distally based strip of flexor carpi radialis tendon passed through the first metacarpal, without arthroplasty, to restore a static restraint against dorsal translation in the lax trapeziometacarpal joint.³⁶ However, for ligament-only reconstruction to be successful long-term, articular surfaces must be eburnation-free and display only minimal early changes, which can be best assessed intraoperatively.^{10,36}

Extension osteotomy is also a reported option at this stage, provided the joint wear does not extend beyond the volar surface.⁴³ Studies that describe the mostly palmar patterns of articular surface destruction provide the rationale for treatment by means of extension metacarpal osteotomy, which transfers the stress load dorsally, as an alternative to trapeziectomy and ligament arthroplasty in young, active patients.^{31,49,50}

Treatment of stage II disease may vary, depending on the status of the articular wear pattern seen intraoperatively. Mild stage II disease does not require resurfacing or trapezium excision procedures and can be treated like stage I disease. More advanced stage II disease may require joint resurfacing by means of dorsal load transference with a closing wedge⁵¹ or extension osteotomy,⁴³

Table 3. Differential Diagnoses of Trapeziometacarpal Osteoarthritis

De Quervain's disease
Flexor carpi radialis tenosynovitis
Trigger thumb
Subsesamoid arthritis
Scaphoid fracture (distal pole)

provided arthritic changes spare the dorsal trapeziometacarpal joint. More advanced wear patterns (assessed intraoperatively) require trapezium excision and formal ligament reconstruction tendon interposition-type arthroplasty. Arthrodesis of the trapeziometacarpal joint may be indicated in younger patients (often with a posttraumatic cause) who have high joint demands, requiring strong grip and pinch, because of their occupation.⁵² However, this continues to be controversial, as some may still be good candidates for ligament reconstruction tendon interposition arthroplasty procedures. However, arthrodesis non-union rates have been reported as being anywhere from 5⁵³ to 50 percent.⁵⁴

Stage III patients require more than beak ligament reconstruction alone. Trapezium excision (whole or partial), with or without interposition material (e.g., tendon, allograft, autograft), and with or without ligament reconstruction is required. The authors of this report favor ligament reconstruction with either tendon (ligament reconstruction tendon interposition) interposition or a costochondral autograft. Stage IV suggests scaphotrapezium joint involvement, possibly along with other articular surfaces (trapezium-trapezoidal and trapezium-second metacarpal joints). Pantrapezium and/or scaphotrapezium joint involvement requires complete trapezium excision or double arthroplasty. Ligament reconstruction tendon interposition or suspensionplasty^{19,55} procedures with articular resurfacing in this stage have been shown to provide good pain relief and thumb function.

Recently, some surgeons have returned to trapezium excision alone as first described by Gervis,⁵⁶ without tendon interposition or ligament reconstruction.^{21,23,26,27,56} Referred to by some as a "hematoma arthroplasty,"²³ trapezium excision alone has had favorable results, based on short-term studies.^{21,23,26,27,56} Although it is believed that loss of trapezium height does not correlate directly with function or pain levels, long-term loss of trapezium height can lead to scaphoid impingement, which may compromise outcomes.³⁶ Long-term prospective studies are still needed. Nevertheless, if trapezium excision alone is to be performed, Kirschner wire fixation becomes critical, as short-term height loss may occur, leading to degenerative disease in the distal pole of the scaphoid.²⁴ In contrast, long-term evidence supporting ligament reconstruction tendon interposition arthroplasty does exist,¹⁷ and it continues to be a mainstay in surgical treatment of trapeziometacarpal joint disease.

Ligament Reconstruction Tendon Interposition Arthroplasty

In 1973, Eaton and Littler⁴ described reconstruction of the anterior oblique beak ligament by using a distally based half radial portion of the flexor carpi radialis tendon. The flexor carpi radialis tendon is passed through a bony channel at the base of the first metacarpal to its dorsum, where it is routed around the abductor pollicis longus and then back onto itself. This reinforces the volar, dorsal, and radial aspects of the trapeziometacarpal joint capsule. The tenets of this procedure were later reinforced by Burton and Pellegrini,¹⁵ whose rationale for developing the ligament reconstruction tendon interposition arthroplasty focused on the three principles listed previously.^{15,16,57,58} Several modifications have been made to the original procedure, including excision of the entire trapezium and use of the entire width of the flexor carpi radialis tendon.

The surgical technique of ligament reconstruction tendon interposition arthroplasty is outlined in Table 4 and illustrated in Figures 4 through 8. A triradiate, V-shaped, or Wagner type incision is made, centered over the trapezium. A

Table 4. Ligament Reconstruction Tendon Interposition Technique

-
- Make longitudinal (Wagner) or triradiate incision dorsally over trapeziometacarpal joint
 - Mobilize, retract, and protect radial artery and dorsal radial sensory branches
 - Open capsule to inspect trapezoid, trapeziometacarpal joint, and scaphotrapezium joint
 - Section and remove trapezium with bony rongeur
 - Drill oblique channel through metacarpal, 1 cm from base and exiting base in nail plane (Mitek anchor suture fixation can be used instead)
 - Release the flexor carpi radialis tendon at its musculotendinous junction by means of a 2-cm transverse incision
 - Deliver flexor carpi radialis tendon into the arthroplasty site
 - Mobilize the tendon to the second metacarpal insertion (be careful to not detach tendon)
 - Pass tendon through the bony tunnel with loop wire or tendon passer
 - Suspend the thumb metacarpal at the index carpometacarpal joint level, in key pinch position (Kirschner pin can be placed at this point according to the surgeon's preference)
 - Pull the flexor carpi radialis tight and suture it with nonabsorbable braided suture to the metacarpal base periosteum
 - Suture weave the flexor carpi radialis into the anchovy and suture the anchovy to the capsule at multiple deep fixation points
 - Close capsule and skin
 - Place in short arm thumb spica cast
-

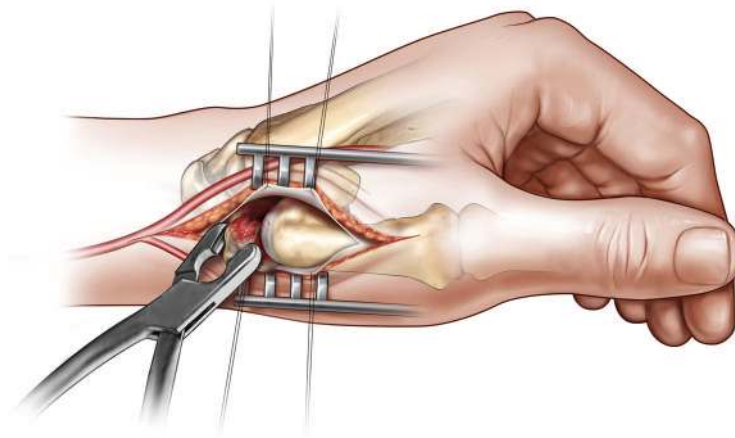


Fig. 4. The trapezium is excised.

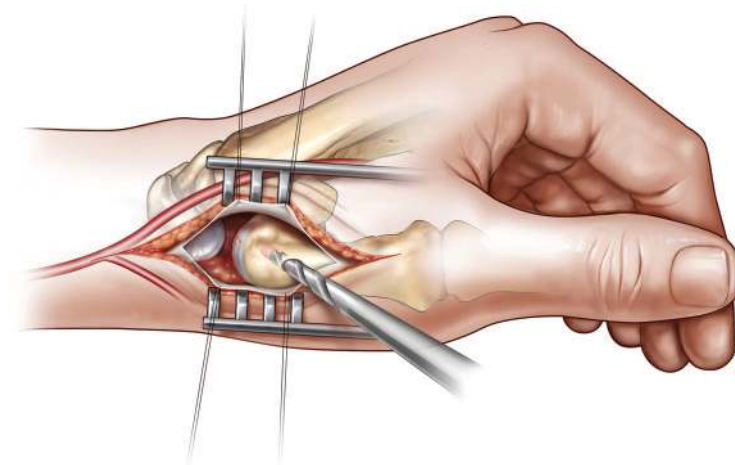


Fig. 5. A bone tunnel is made in the thumb metacarpal base.

longitudinal incision facilitates simultaneous de Quervain's release. The radial dorsal sensory nerves need to be identified and protected from injury. Small vessels from the radial artery are coagulated. The capsule is opened longitudinally. While traction is applied, the trapezoid, trapeziometacarpal, and scaphotrapezial joints are evaluated. The trapezium is excised through an initial saw cut and removed piecemeal with a bony rongeur. Care should be taken to avoid injuring the flexor carpi radialis tendon, as it may pass through a volar trapezial groove. An oblique hole is then made in the dorsal metacarpal cortex, 1 cm distal to the metacarpal base, within the plane of the nail, and directed into the trapezial space. A wire-passing drill can be used effectively for this. An alternative method is Mitek fixation of the flexor carpi radialis tendon to the thumb metacarpal base without making bony channels. Careful attention to complete removal of osteophytes on the

metacarpal side of the trapeziometacarpal joint is critical.

Next, the flexor carpi radialis tendon is retrieved distally in the operative site, after it is transected at its musculotendinous junction by means of a separate 2-cm transverse incision. The tendon is mobilized to its insertion at the second metacarpal base. It is important to keep the tendon moistened with gauze soaked in normal saline, as desiccation can weaken the tendon and lead to fraying, particularly during passage through the metacarpal tunnel. Tendon delivery through the bony tunnels can be facilitated with a 26- or 30-gauge monofilament loop wire. After longitudinal traction is applied to the thumb to bring the base level with the index metacarpal, the flexor carpi radialis tendon is pulled tightly to remove any slack and then is sutured to the metacarpal periosteum and back onto itself with 3-0 nonabsorbable sutures.

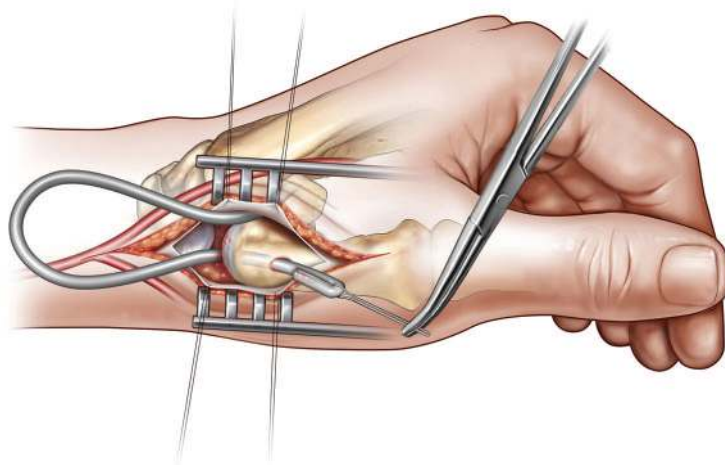


Fig. 6. The entire flexor carpi radialis tendon is passed through the bony channel, aided by a wire loop.

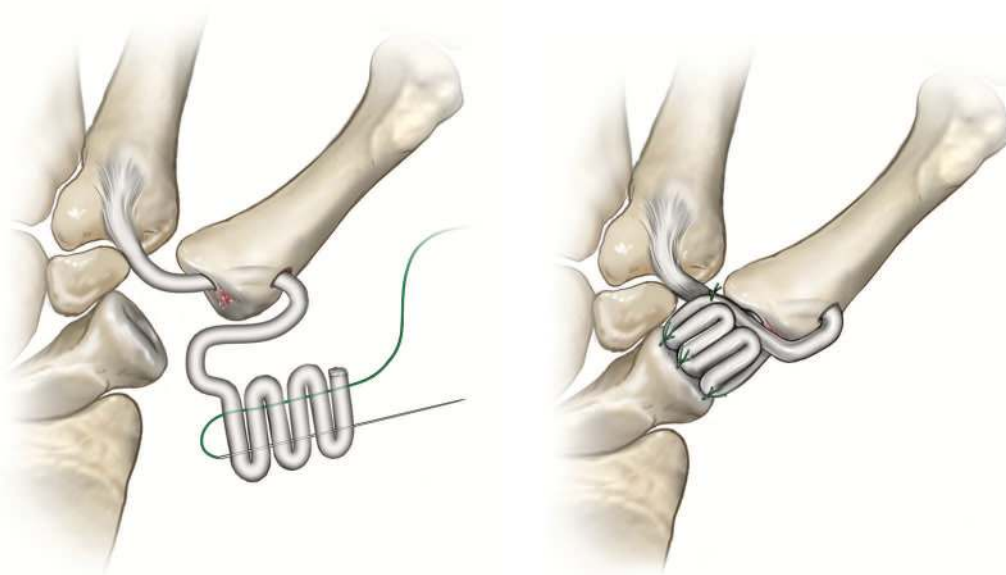


Fig. 7. (Left) The flexor carpi radialis tendon is “anchovied” using permanent suture on a straight needle. (Right) After tension is set and the interposition “anchovy” is made, the entire interposition mass is secured with multiple capsular and periosteal tacking sutures.

Kirschner wire stabilization to the scaphoid may be used if preferred. The suture is then weaved into the remaining flexor carpi radialis remnant along its length to create the interposition mass (anchovy), which is anchored deeply to the joint capsule. The capsule should be closed with non-absorbable suture material, and skin is closed with a running 4-0 nylon horizontal suture, alternating with simple sutures.

Intraoperative radiographs should be viewed to assess the trapezial space and metacarpal position. The thumb metacarpophalangeal joint

should also be evaluated for instability. If there is greater than 30 degrees of valgus instability or 30 degrees of passive hyperextension instability, arthrodesis or capsulodesis in 10 degrees of flexion should be performed.⁵⁹

The postoperative regimen consists of immobilization with a short arm thumb-spica cast for 4 weeks. After 4 weeks, range-of-motion exercises are begun, with active motion of the thumb interphalangeal and metacarpophalangeal (if not arthrodesed) joints. Isometric thenar muscle exercises can also be initiated. During this period,

the thumb spica splint may be removed four times a day to facilitate exercising. Eight weeks postoperatively, active flexion-adduction exercises at the thumb basal joint begin and the splint is weaned off. Resistive lateral pinch and grip strengthening is initiated at 12 weeks with titration of normal activity.

Ligament Reconstruction Tendon Interposition Results

Tomaino et al.¹⁷ evaluated the results of ligament reconstruction tendon interposition arthroplasty on 24 thumbs with an average of 9 years' follow-up. They reported 95 percent of the 22 patients studied as having excellent pain relief and satisfaction, even with activities that required significant lateral pinch (i.e., opening jars and using keys). Average grip strength improved 93 percent compared with preoperative values; tip pinch strength improved 65 percent; and key pinch improved 34 percent, taking 6 years to reach preoperative values. Thumb tips were able to touch the little finger base in 92 percent of the thumbs that were operated on. Average subluxation of the metacarpal base was 11 percent at 9 years, and the average arthroplasty space height decrease was 13 percent. Similar to previous reports of even greater metacarpal proximal migration,^{22,28,60} no relation to clinical outcomes has been seen.

Other reports with shorter follow-up intervals have also shown positive outcomes with ligament reconstruction tendon interposition arthroplasty. Lins et al.²² studied 30 thumbs at 3.5 years' average follow-up and found an average of 50 percent improvement in grip strength and 43 percent improvement in key pinch. In 1997, Rayan and Young²⁸ reported results based on an average of 3.2 years' follow-up, with less impressive outcomes of 13 percent grip strength improvement with 27 percent decline in key pinch. However, the authors' results are based on contralateral hand measurements rather than same-hand preoperative values. Similar to other studies, 85 percent of Rayan and Young's²⁸ study patients experienced pain relief. Two of the largest series, by Nylen et al.⁶¹ (100 procedures) and Varitimidis et al. (62 thumbs),⁶² revealed findings similar to those of previous reports with respect to pain, function, and patient satisfaction.

Technical Variations

Numerous technical variations of ligament reconstruction tendon interposition arthroplasty have been described in the literature. Some vari-

ations simply alter specific steps in the operation. Harvesting of the entire flexor carpi radialis versus one-half flexor carpi radialis has not been shown to produce any more morbidity, with respect to wrist strength or endurance.^{62,63} There are no reports comparing the importance of pin fixation of the metacarpal with no pin fixation, and the authors of this article do not see the necessity, provided adequate interposition material has been placed. Vartimidis et al.⁶² believe that lack of Kirschner wire stabilization may actually eliminate a potential source of complications.

The decision to perform partial versus whole trapezium resection can be based on the amount of radiographic and intraoperative scaphotrapezium disease and pantrapezium involvement. Most authors agree that if there is pantrapezium or scaphotrapezium disease progression, the entire trapezium should be resected. Glickel et al.⁴¹ reported that scaphotrapezium symptomatology did not advance during an average 8-year follow-up period in 18 patients after ligament reconstruction tendon interposition arthroplasty with hemitrapeziectomy. Irwin et al.⁶⁴ attributed unrecognized scaphotrapezoid involvement as a cause of postoperative discomfort. There is no long-term or short-term morbidity with complete trapezium excision when ligament reconstruction tendon interposition is performed.¹⁷ Given the high possibility for unrecognized scaphotrapezium disease, we recommend pantrapezium excision when performing ligament reconstruction tendon interposition arthroplasty.

Other variations of ligament reconstruction tendon interposition center on the use of different tendons, variations of tendon configurations, and/or interposition material. Thompson⁶⁵ described a technical modification using the abductor pollicis longus, rather than the flexor carpi radialis tendon. The technique involves detaching half of the abductor pollicis longus at its musculotendinous junction, and leaving its dorsal attachment to the thumb metacarpal intact. The abductor pollicis longus is then passed retrograde through the dorsal bone hole and out the articular surface hole. The abductor pollicis longus tendon is then passed through a second oblique bone tunnel from the trapezium facet of the index metacarpal and heading dorsoulnarly on the index metacarpal. Tension is set by pulling on the abductor pollicis longus tail that emerges from the dorsal index metacarpal hole. Next, the abductor pollicis longus is woven into the extensor carpi radialis brevis tendon for added stability. Originally, this technique was intended for silicone ar-

throplasty salvage and only later became a primary procedure.

Diao^{18,66} modified the “Thompson suspension-plasty” by orienting the second bone tunnel in the palmar portion of the metaphyseal-diaphyseal junction of the index metacarpal and drilling it dorsally. Diao believes this variation adds (1) added bony stability with more cortical bone hole support and (2) a more distal suspension focus.¹⁸ Results in 38 patients, with 15 thumbs, followed at an average of 23 months, showed complete pain relief in 87 percent, with full opposition and flexion in all but one patient.¹⁸ In the same report,¹⁸ cadaveric analysis demonstrated the least proximal migration when compared with ligament reconstruction tendon interposition and Thompson suspensionplasty.

Since Froimson⁶⁷ added a rolled-up flexor carpi radialis tendon anchovy as interposition material in the trapezoidal space, other materials such as silicone rubber spacers^{68–73} have been proposed. Silicone implants, particularly in the trapeziometacarpal joint, have been plagued with many problems, including silicone synovitis, bone cysts, bony erosions, implant fracturing, and high instability rates (66 percent).⁷³ As a result, most surgeons have moved away from their use in thumb trapeziometacarpal joint reconstruction. A more viable option for interposition material has been described by Trumble et al.,²⁰ who used a costochondral allograft spacer, with flexor carpi radialis tendon passing through it, in 46 thumbs. At a mean follow-up of 42 months, 90 percent of patients had a high level of function, with minimal symptoms. The trapeziometacarpal space had decreased 21 percent after surgery, and trapeziometacarpal subluxation was 16 percent versus 21 percent preoperatively.²⁰ Kirschner wire fixation is not required, and the anterior oblique ligament is not reconstructed with this technique. The senior author (S.N.O) has had good experience with a technique similar to that of Trumble et al.²⁰ but which uses rib autograft, and now prefers this technique almost exclusively.

CONCLUSIONS

Trapeziometacarpal arthritis is the second most common degenerative joint disease in the hand.^{1–4} It has been postulated to be caused by hormonal and biochemical factors; increased ligament laxity; and the presence of a smaller, less congruous trapeziometacarpal joint.^{8,9} In the year 2005, the beak ligament continues to be considered the primary trapeziometacarpal joint stabi-

lizer, and is still implicated in the pathogenesis of trapeziometacarpal joint arthritis.³⁶ Current techniques that restore trapeziometacarpal joint stability through ligamentous reconstruction such as the ligament reconstruction tendon interposition arthroplasty continue to produce consistently favorable results. Numerous technical variations of ligament reconstruction and tendon interposition arthroplasty, originally popularized by Burton and Pelligrini,¹⁵ have been described in the literature,^{16–20} and all center on three common principles: (1) excision of the diseased trapezium; (2) reconstruction of the beak ligament; and (3) interposition of a tissue substance to maintain metacarpal position. The validity and longevity of ligament reconstruction tendon interposition arthroplasty procedures^{17,19,20,22,28,62} have withstood the test of time, and the procedure results in high patient satisfaction.

Ashkan Ghavami, M.D.

Department of Plastic and Reconstructive Surgery
The University of Texas Southwestern Medical Center
5323 Harry Hines Boulevard
Dallas, Texas 75390-9132
ashghavami@sbcglobal.net

REFERENCES

1. Carroll, R. E., and Hill, N. A. Arthrodesis of the carpo-metacarpal joint of the thumb. *J. Bone Joint Surg. (Br.)* 55: 292, 1973.
2. Peyron, J. G. Osteoarthritis: The epidemiologic viewpoint. *Clin. Orthop.* 213: 13, 1986.
3. Pellegrini, V. D. Osteoarthritis of the trapeziometacarpal joint: The pathophysiology of articular cartilage degeneration. I. Anatomy and pathology of the aging joint. *J. Hand Surg. (Am.)* 16: 967, 1991.
4. Eaton, R. G., and Littler, J. W. Ligament reconstruction for the painful thumb carpometacarpal joint. *J. Bone Joint Surg. (Am.)* 55: 1655, 1973.
5. Kelsey, J. L., Pastides, H., Kreiger, N., et al. *Upper Extremity Disorders: A Survey of Their Frequency and Cost in the United States*. St. Louis, Mo.: Mosby, 1980.
6. Armstrong, A. L., Hunter, J. B., and Davis, T. R. The prevalence of degenerative arthritis of the base of the thumb in post-menopausal women. *J. Hand Surg. (Br.)* 19: 340, 1994.
7. Lane, L. B., and Eaton, R. G. Ligament reconstruction for the painful “prearthritic” thumb carpometacarpal joint. *Clin. Orthop.* 220: 52, 1987.
8. Katarincic, J. A. Thumb kinematics and their relevance to function. *Hand Clin.* 17: 169, 2001.
9. Xu, L., Strauch, R. J., Ateshian, G. A., et al. Topography of the osteoarthritic thumb carpometacarpal joint and its variation with regard to gender, age, site, and osteoarthritic stage. *J. Hand Surg. (Am.)* 23: 454, 1998.
10. Freedman, D. M., Eaton, R. G., and Glickel, S. Z. Long term result of volar ligament reconstruction for symptomatic basal joint laxity. *J. Hand Surg. (Am.)* 25: 297, 2000.
11. Linscheid, R. The thumb axis joints: A biomechanical model. In *Difficult Problems in Hand Surgery*. St. Louis, Mo.: Mosby, 1982.

12. Eaton, R. G., Lane, L. B., Littler, J. W., et al. Ligament reconstruction for the painful thumb carpometacarpal joint: A long-term assessment. *J. Hand Surg. (Am.)* 9: 962, 1984.
13. Bettinger, P. C., Linscheid, R. L., Berger, R. A., Cooney, W. P., and An, K. N. An anatomic study of the stabilizing ligaments of the trapezium and trapeziometacarpal joint. *J. Hand Surg. (Am.)* 24: 786, 1999.
14. Bettinger, P. C., and Berger, R. A. Functional ligamentous anatomy of the trapezium and trapeziometacarpal joint (gross and arthroscopic). *J. Hand Surg. (Am.)* 17: 151, 2001.
15. Burton, R. I., and Pellegrini, V. D. Surgical management of basal joint arthritis of the thumb: Part II. Ligament reconstruction with tendon interposition arthroplasty. *J. Hand Surg. (Am.)* 11: 324, 1986.
16. Tomaino, M. M. Ligament reconstruction tendon interposition arthroplasty for basal joint arthritis: Rationale, current technique and clinical outcome. *J. Hand Surg. (Am.)* 17: 207, 2001.
17. Tomaino, M. M., Pellegrini, Jr., V. D., and Burton, R. I. Arthroplasty of the basal joint of the thumb: Long term follow-up after ligament reconstruction with tendon interposition. *J. Bone Joint Surg. (Am.)* 77: 346, 1995.
18. Diao, E. Trapezio-metacarpal arthritis: Trapezium excision and ligament reconstruction not including the LRTI arthroplasty. *J. Hand Surg. (Am.)* 17: 223, 2001.
19. Kleinman, W. B., and Eckenrode, J. F. Tendon suspension sling arthroplasty for thumb trapeziometacarpal arthritis. *J. Hand Surg. (Am.)* 16: 983, 1991.
20. Trumble, T. E., Rafijah, G., Gilbert, M., Allan, C. H., North, E., and McCallister, W. V. Thumb trapeziometacarpal joint arthritis: Partial trapeziectomy with ligament reconstruction and interposition costochondral allograft. *J. Hand Surg. (Am.)* 25: 61, 2000.
21. Gervis, W. H. Excision of the trapezium for osteoarthritis of the trapezio-metacarpal joint. *J. Bone Joint Surg. (Br.)* 31: 537, 1949.
22. Lins, R. E., Gelberman, R. H., Mckeown, L., et al. Basal joint arthritis: Trapeziectomy with ligament reconstruction and tendon interposition arthroplasty. *J. Hand Surg. (Am.)* 21: 202, 1996.
23. Jones, N. F., and Maser, B. M. Treatment of arthritis of the trapeziometacarpal joint with trapeziectomy and hematoma arthroplasty. *J. Hand Surg. (Am.)* 17: 237, 2001.
24. Varley, G. W., Calvey, J., Hunter, J. V., Barton, N. J., and Davis, T. R. Excision of the trapezium for osteoarthritis at the base of the thumb. *J. Bone Joint Surg. (Br.)* 76: 964, 1994.
25. Kuhns, C. A., Emerson, E. T., and Meals, R. A. Hematoma and distraction arthroplasty for thumb basal joint osteoarthritis: A prospective, single-surgeon study including outcome measures. *J. Hand Surg. (Am.)* 28: 381, 2003.
26. Davis, T. R. C., Brady, O., Barton, N. J., Lunn, P. G., and Burke, F. D. Trapeziectomy alone, with tendon interposition or with ligament reconstruction? *J. Hand Surg. (Br.)* 6: 689, 1997.
27. Davis, T. R. C., Brady, O., and Dias, J. J. Excision of the trapezium for osteoarthritis of the trapeziometacarpal joint: A study of the benefit of ligament reconstruction or tendon interposition. *J. Hand Surg. (Am.)* 29: 1069, 2004.
28. Rayan, G. M., and Young, B. T. Ligament reconstruction arthroplasty for trapeziometacarpal arthrosis. *J. Hand Surg. (Am.)* 25: 447, 2000.
29. Eaton, R., and Littler, J. A study of the basal joint of the thumb: Treatment of its disabilities by fusion. *J. Bone Joint Surg. (Am.)* 51: 661, 1969.
30. Doershuck, S. H., Hicks, D. G., Chinchilli, V. M., et al. Histopathology of the palmar beak ligament in trapeziometacarpal osteoarthritis. *J. Hand Surg. (Am.)* 24: 496, 1999.
31. Pellegrini, V. D. Pathomechanics of the thumb trapeziometacarpal joint. *J. Hand Surg. (Am.)* 17: 175, 2001.
32. Pellegrini, V. D., Jr. Olcott, C., Hollenberg, G., et al. Contact patterns in the trapeziometacarpal joint: Effects of volar beak ligament division and extension metacarpal osteotomy. *J. Hand Surg. (Am.)* 18: 238, 1993.
33. Pellegrini, V. D., Jr. Osteoarthritis of the trapeziometacarpal joint: The pathophysiology of articular cartilage degeneration: I. Anatomy and pathology of the aging joint. *J. Hand Surg. (Am.)* 16: 967, 1991.
34. Pellegrini, V. D., Jr. Osteoarthritis of the trapeziometacarpal joint: The pathophysiology of articular cartilage degeneration. II. Articular wear patterns in the osteoarthritic joint. *J. Hand Surg. (Am.)* 16: 975, 1991.
35. Haines, R. The mechanism of rotation of the first carpometacarpal joint. *J. Anat.* 78: 44, 1944.
36. Tomaino, M. M. Thumb basal joint arthritis. In D. P. Green et al. (Eds.), *Green's Operative Hand Surgery*, 5th Ed. New York: Churchill Livingstone, 2005. Pp. 461-485.
37. Lanz, T. V., and Wachsmuth, W. *Praktische Anatomie; Einlehr- und Hilfsbuch der Anatomischen Grundlagen Arzt Handelns*. Berlin: Springer-Verlag, 1959. P. 261.
38. Burton, R. I. Basal joint arthrosis of the thumb. *Orthop. Clin. North Am.* 4: 347, 1973.
39. Dell, P. C., Brushart, T. M., and Smith, R. J. Treatment of trapeziometacarpal arthritis: Results of resection arthroplasty. *J. Hand Surg. (Am.)* 3: 243, 1978.
40. Eaton, R. G., and Glickel, S. Z. Trapeziometacarpal osteoarthritis: Staging as a rationale for treatment. *Hand Clin.* 3: 455, 1987.
41. Glickel, S. Z., Korstein, A. N., and Eaton, R. G. Long-term follow-up of trapeziometacarpal arthroplasty with coexisting scaphotrapezoidal disease. *J. Hand Surg. (Am.)* 17: 612, 1992.
42. Glickel, S. Z. Clinical assessment of the thumb trapeziometacarpal joint. *J. Hand Surg. (Am.)* 17: 185, 2001.
43. Tomaino, M. M. Treatment of Eaton stage I trapeziometacarpal disease: Ligament reconstruction or thumb metacarpal extension osteotomy? *Hand Clin.* 17: 197, 2001.
44. Florack, T. M., Miller, R. J., Pellegrini, Jr., V. D., et al. The prevalence of carpal tunnel syndrome in patients with basal joints arthritis of the thumb. *J. Hand Surg. (Am.)* 17: 624, 1992.
45. Day, C. S., Gelberman, R., Patel, A. A., et al. Basal joint osteoarthritis of the thumb: A prospective trial of steroid injection and splinting. *J. Hand Surg. (Am.)* 29: 247, 2004.
46. Carr, M. M., and Freiberg, A. Osteoarthritis of the thumb: Clinical aspects and management. *Am. Fam. Physician* 50: 995, 1994.
47. Pomerance, J. F. Painful basal joint arthritis of the thumb: Part I. Anatomy, pathophysiology, and diagnosis. *Am. J. Orthop.* 24: 401, 1995.
48. Swigart, C. R., Eaton, R. G., Glickel, S. Z., and Johnson, C. Splinting in the treatment of arthritis of the first carpometacarpal joint. *J. Hand Surg. (Am.)* 24: 86, 1999.
49. Molitor, P., Emery, R., and Meggitt, B. First metacarpal osteotomy for carpometacarpal osteoarthritis. *J. Hand Surg. (Br.)* 16: 424, 1994.
50. Wilson, J. Basal osteotomy of the first metacarpal in the treatment of arthritis of the carpometacarpal joint of the thumb. *Br. J. Surg.* 60: 854, 1973.
51. Pellegrini, V. D., Jr., Extension metacarpal osteotomy in the treatment of trapeziometacarpal osteoarthritis. *Atlas of the Hand Clinics: Carpometacarpal Joint* 2: 183, 1997.

52. Klimo, G. F., Verma, R. B., and Baratz, M. E. The treatment of trapeziometacarpal arthritis with arthrodesis. *Hand Clin.* 17: 261, 2001.
53. Leach, R. E., and Bolton, P. E. Arthritis of the carpometacarpal joint of the thumb: Results of arthrodesis. *J. Hand Surg. (Am.)* 50: 1171, 1968.
54. Mattsson, H. S. Arthrodesis of first carpometacarpal joint for osteoarthritis. *Acta Orthop. Scand.* 40: 602, 1969.
55. Thompson, J. S. Surgical treatment of trapeziometacarpal arthrosis. *Adv. Orthop. Surg* 10: 105, 1996.
56. Murley, A. Excision of the trapezium in osteoarthritis of the first carpometacarpal joint. *J. Bone Joint Surg. (Br.)* 42: 502, 1960.
57. Schmidt, C. C., McCarthy, D. M., Arnoczky, S. P., et al. Basal joint arthroplasty using an allograft tendon interposition versus no interposition: A radiographic, vascular, and histologic study. *J. Hand Surg. (Am.)* 25: 447, 2000.
58. Tomaino, M. M., and Burton, R. I. Ligament reconstruction with tendon interposition arthroplasty for the thumb carpometacarpal joint. In W. F. Blair and C. M. Steyers (Eds.), *Techniques in Hand Surgery*. Baltimore: Williams & Wilkins, 1996. Pp. 952–960.
59. Mankin, H. J. The response of articular cartilage to mechanical injury. *J. Bone Joint Surg. (Am.)* 64: 460, 1982.
60. Tomaino, M. M., and King, J. Ligament reconstruction tendon interposition arthroplasty for basal joint arthritis: Simplifying flexor carpi radialis tendon passage through the thumb metacarpal. *J. Orthop.* 29: 49, 2000.
61. Nylén, S., Johnson, A., and Rosenquist, A.-M. Trapeziectomy and ligament reconstruction for osteoarthritis of the base of the thumb. *J. Hand Surg. (Am.)* 18: 616, 1993.
62. Varitimidis, S. E., Fox, R. J., King, J. A., et al. Trapeziometacarpal arthroplasty using the entire flexor carpi radialis tendon. *Clin. Orthop.* 370: 164, 2000.
63. Tomaino, M. M., and Coleman, K. Use of the entire width of the flexor carpi radialis tendon for the ligament reconstruction tendon interposition arthroplasty does not impair wrist function. *J. Orthop.* 29: 283, 2000.
64. Irwing, A. S., Maffulli, N., and Chesney, R. B. Scapho-trapezoid arthritis: A cause of residual pain after arthroplasty of the trapezio-metacarpal joint. *J. Hand Surg. (Am.)* 20: 346, 1995.
65. Thompson, J. S. Complications and salvage of trapeziometacarpal arthroplasties. *Instr. Course Lect.* 38: 3, 1989.
66. Thompson, S. Suspensionplasty technique. *Atlas Hand Clin.* 2: 2, 1997.
67. Froimson, A. I. Tendon arthroplasty of the trapeziometacarpal joint. *Clin. Orthop.* 70: 191, 1970.
68. Swanson, A. B., and De Groot Swanson, G. Reconstruction of the thumb basal joint: Development and current status of implant techniques. *Clin. Orthop.* 220: 68, 1987.
69. Swanson, A. B. Disabling arthritis at the base of the thumb: Treatment by resection of the trapezium and flexible (silicone) implant arthroplasty. *J. Bone Joint Surg. (Am.)* 54: 456, 1972.
70. Smith, R. J., Atkinson, R. E., and Jupiter, J. B. Silicone synovitis of the wrist. *J. Hand Surg. (Am.)* 10: 47, 1985.
71. Dekel, S., and Weissman, S. L. Joint changes after overuse and peak overloading of rabbit knees in vivo. *Acta Orthop. Scand.* 49: 519, 1978.
72. Amadio, P., Millender, L., and Smith, R. Silicone spacer or tendon spacer for trapezium resection arthroplasty: Comparison of results. *J. Hand Surg. (Am.)* 7: 237, 1982.
73. Richard, A. R., and Ghazi, M. R. Treatment of trapeziometacarpal arthritis with silastic and metallic implant arthroplasty. *J. Hand Surg. (Am.)* 17: 245, 2001.